

# Fallopian Tube Carcinoma

Marina Stasenکو, MD<sup>1</sup>; Olga Fillipova, MD<sup>1</sup>; and William P. Tew, MD<sup>1</sup>

Primary fallopian tube carcinoma is a rare and difficult to cure disease. It is often grouped under the epithelial ovarian cancer umbrella, together with primary ovarian and peritoneal carcinomas. More recent evidence has suggested that epithelial ovarian cancers originate from a fallopian tube precursor. The mainstay of treatment is surgical cytoreduction and platinum-based chemotherapy. There is much debate over the best timing for surgery and the best approach to delivering the chemotherapy: traditional intravenous once every 3 weeks regimen, versus intraperitoneal, versus dose-dense intravenous regimens. Although these debates continue, novel targeted therapies, including bevacizumab and poly(adenosine diphosphate [ADP]-ribose) polymerase (PARP) inhibitors, have emerged. PARP inhibitors are particularly efficacious in patients with *BRCA1/2* gene mutations, and their use has been shown to prolong patient survival. This article reviews the pathologic etiology; describes the heredity, treatment challenges, and controversies; and summarizes novel therapies in primary fallopian tube carcinoma.

**J Oncol Pract 15:375-382. © 2019 by American Society of Clinical Oncology**

## INTRODUCTION

Fallopian tube serous carcinoma (FTC) originates from the transformation of the salpingeal mucosa. Throughout the literature, epithelial ovarian cancer is often used as an umbrella term incorporating ovarian, fallopian tube, and primary peritoneal carcinomas. Although the cellular precursor of these malignancies is still in question, the dissemination patterns are indistinguishable, and clinical behavior, response to surgery, and chemosensitivity are so similar that the same treatment paradigm is applied to all three diseases.

When grouped together, ovarian, fallopian tube, and primary peritoneal carcinomas account for 2.5% of all new female cancer cases in the United States (an incidence rate of 11.6 per 100,000 women per year, amounting to more than 22,000 diagnoses each year).<sup>1,2</sup> Despite its relative rarity, epithelial ovarian cancer is the fifth-leading cause of cancer-related deaths, responsible for more than 14,000 deaths annually (7.2 deaths per 100,000).<sup>2</sup> The 5-year survival rate is 47.4%. If the disease is caught in early stages, survival is as high as 92%. Unfortunately because of a lack of good screening modalities, most diagnoses occur in advanced stages, where the 5-year survival rate is less than 30%.<sup>3</sup>

There are four major histologic types of epithelial ovarian cancer: serous, endometrioid, mucinous, and clear cell carcinoma. Because epithelial ovarian

cancers are a heterogeneous group of malignancies both histologically and molecularly, a dichotomous classification system has been proposed: type I tumors are confined to the ovary, genetically stable, and include low-grade serous, mucinous, endometrioid, and clear cell carcinomas; type II tumors present at advanced stages, have a high level of chromosomal instability, and include high-grade serous, undifferentiated, and carcinosarcomas.<sup>4</sup> High-grade serous carcinomas (HGSC) are characterized by *TP53* mutation in more than 95% of cases. No other mutation is seen consistently in nonfamilial HGSC, although the inactivation of the *BRCA1/2* genes by mechanisms such as hypermethylation can be seen in as many as 40% to 50% of sporadic cases.<sup>5</sup> FTC falls primarily into this the latter category of tumor.

Given the rarity of the disease, prospective literature on primary FTC is limited. Studies that have focused on primary FTC have noted an incidence rate of 0.36 to 0.41 per 100,000 women per year, amounting to approximately 300 to 400 annual cases.<sup>6,7</sup> Wethington et al<sup>8</sup> used the SEER database to examine the outcomes of women with FTC compared with those with ovarian cancer. The authors noted the median age of diagnosis to be 64 years for both groups. However, women with FTC were more likely to be diagnosed with early-stage tumors and to have an improved overall and cancer-specific survival when compared with women with primary ovarian cancer.

## ASSOCIATED CONTENT

See accompanying commentary on page 383

Author affiliations and support information (if applicable) appear at the end of this article.

Accepted on January 29, 2019 and published at [jop.ascopubs.org](http://jop.ascopubs.org) on July 8, 2019; DOI <https://doi.org/10.1200/JOP.18.00662>

This article focuses on HGSC of the fallopian tube and reviews the pathologic and molecular etiology; describes hereditary FTC, treatment challenges, and controversies; and touches on novel therapies including poly(adenosine diphosphate [ADP]-ribose) polymerase (PARP) inhibitors and immunotherapy.

### SEROUS TUBAL INTRAEPITHELIAL NEOPLASIA

HGSC accounts for 70% to 80% of epithelial histologies and originates from the Müllerian epithelium. Once formed, cancer cells disseminate primarily within the peritoneal or pleural cavity, with only superficial invasion of organs.<sup>9</sup> Although historic dogma postulated that epithelial ovarian cancer originated from the surface epithelium of the ovary and developed as a result of incessant ovulation and repetitive surface trauma, more recent research has challenged this theory.<sup>10</sup> Over the past decade, an abundance of evidence has been presented to support the theory that all epithelial carcinomas have an extraovarian, and more specifically a fallopian tube, origin.<sup>11-13</sup>

Epidemiologic studies have linked factors that increase lifetime ovulation cycles with increased risk of epithelial ovarian cancer. These include nulliparity, early menarche, and late menopause.<sup>14</sup> Therefore, conversely, factors that decrease lifetime ovulation cycles are protective. For women with a hereditary predisposition toward epithelial ovarian cancer, preventative strategies include the use of oral contraception at a younger age and undergoing risk-reducing bilateral salpingo-oophorectomy (RR-BSO) later in life.<sup>15-17</sup> Examining the pathologic specimen from these risk-reducing surgeries, in 2001, a group of investigators first noted premalignant serous tubal intraepithelial carcinomas (STICs) and occult invasive HGSC in the tubal specimen (particularly in the fimbria of the tubes) that were not present in the ovarian specimens.<sup>12</sup> Additional research confirmed these early lesions in both hereditary and nonhereditary epithelial ovarian cancers.<sup>11,18</sup>

The first step in the transformation of fallopian tube epithelium to carcinoma is the evolution of a single-cell *TP53* mutant epithelial layer, p53 signature, which includes strong p53 immunopositivity and evidence of DNA damage in otherwise normal secretory fallopian tube cells. This event is then followed by the development of the STIC lesion, characterized by an atypical secretory fallopian tube epithelium with a high proliferative index and accumulation of aberrant p53.<sup>19</sup> The STIC lesions then either invade the tubal stroma locally (developing into primary FTC) or exfoliate onto the surface of the ovary or peritoneum (primary ovarian or peritoneal carcinoma)<sup>18</sup> (Fig 1). Several immunohistochemistry and targeted sequencing studies confirmed the presence of the same *TP53* mutant in the premalignant tubal lesions as in the surrounding invasive carcinoma.<sup>18,20</sup> Taking it a step further, Labidi-Galy et al<sup>13</sup> used whole-exome sequencing and structural analysis to compare preinvasive lesions with HGSC in the same patient

and noted that p53 signatures and STICs harbored the same sequence changes and the ancestral clone of the HGSC.

Although no longer thought to be the sole mechanism for HGSC, incessant ovulation does have a role in the STIC model of disease development and progression. It is postulated that ovulation increases the local follicular fluid, which is rich in inflammatory cytokines. Exposure to this environment by the secretory fallopian tube epithelium causes intracellular inflammation and genetic stress, leading to DNA damage and p53 modulated apoptosis. Mutations of *TP53* are more likely to occur after repetitive stress, resulting in a progenitor cell evading apoptosis and expanding to form a detectable p53 signature.<sup>19</sup>

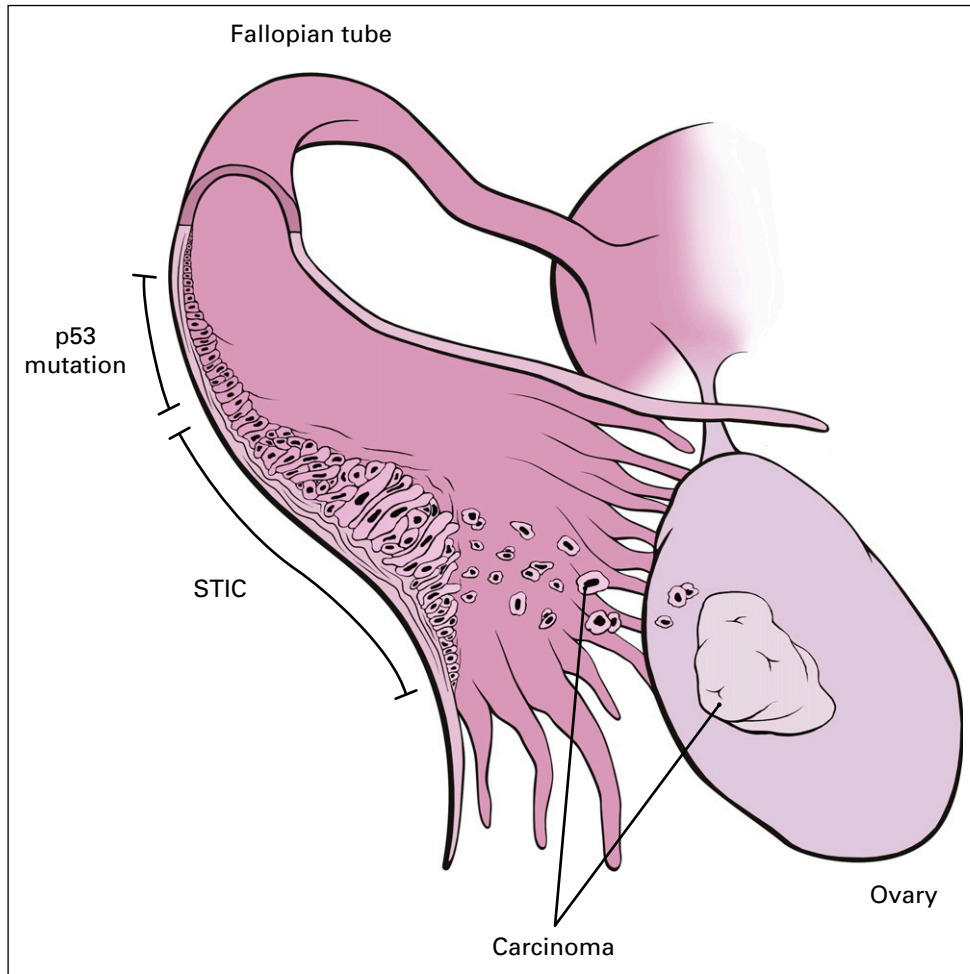
Finally, although STIC lesions have been found with late-stage HGSC in up to 60% of cases, conflicting molecular data do suggest that STIC lesions are not always the source of disseminated HGSC. One study noted that in the small cohort of samples in that study, a portion of STIC lesions molecularly represented metastases to the fallopian tube rather than the inciting lesion.<sup>21</sup>

### INCREASING INCIDENCE OF FTC

With the recognition of STIC lesions as the likely precursor lesions to HGSC, the reported incidence of FTC has increased. Although there has been a decrease in the incidence of ovarian cancer, from 2001 to 2014, the incidence of FTC has increased 4.19-fold.<sup>22</sup> This increase is likely multifactorial: change in diagnostic practices, increased early detection, and improved pathology processing.<sup>23</sup>

With increased awareness of precursor lesions, there is a greater trend to classify HGSC as FTC when STIC lesions are present.<sup>24</sup> Furthermore, the implementation of the Sectioning and Extensive Examination of the Fimbria protocol by pathology departments has led to a general increase in recognition of STICs.<sup>25</sup> As a result, STIC lesions have been found in 3% to 8% of women with hereditary breast and ovarian cancer syndromes who are undergoing RR-BSO, and concurrently with HGSC, 13% to 53% of the time.<sup>21,26,27</sup> Finally, there has been a push for RR-BSO for women at high risk of hereditary breast and ovarian cancer syndromes and opportunistic salpingectomies for women at average risk, thereby increasing detection of precancer and early invasive carcinoma.<sup>17,28</sup> It is worth noting, however, that although STIC lesions are seen relatively frequently in women with hereditary predisposition for FTC, in women without germline mutations who are undergoing surgery for benign indication, STIC or early tubal carcinoma is found less than 1% of the time.<sup>29</sup>

With the theory that a major portion of epithelial ovarian cancers originate from the fallopian tube, the true incidence of FTC will become clearer with time, as more prophylactic and opportunistic salpingectomies are



**FIG 1.** Epithelial ovarian cancer develops from tubular precursor lesion. First step is the evolution of a single cell p53 mutant epithelial layer that then develops into the serous tubular intraepithelial carcinoma (STIC) lesion. STIC lesion either invades locally into the tubal stroma (fallopian tube carcinoma) or exfoliates into the surface of the ovary or peritoneum (ovarian or primary peritoneal carcinoma). From Adam Questell, A KYU Design, with permission.

performed. The incidence of metastatic FTC will decrease with a parallel increase in STIC and early carcinoma detection.

### HEREDITARY FTC

Dysregulation of the homologous recombination repair of double-strand DNA breaks, such as that which occurs with mutations of the *BRCA1* and *BRCA2* genes, predisposes women to hereditary breast and ovarian cancer syndromes.<sup>30</sup> Although up to 20% of all women with epithelial ovarian cancer exhibit a genetic predisposition, only 25% of hereditary breast and ovarian cancer syndromes can be attributed to mutations in *BRCA1/2*.<sup>30</sup> Since the mid-1990s when *BRCA1/2* were noted to be related to hereditary breast and ovarian cancer syndromes, multiple genes in the homologous recombination pathway have emerged as key players, including *ATM*, *BARD1*, *BRIP1*, *CHEK2*, *MRE11A*, *NBN*, *PALB2*, *RAD51C*, and *RAD51D*.<sup>31</sup> A germline deficiency in the homologous recombination repair genes is seen in up to 18% of women with epithelial ovarian cancer, and these patients seem to have an overall favorable prognosis, likely because of improved response to DNA damaging agents such as platinum.<sup>32,33</sup>

Earlier work noted a potential increased prevalence of *BRCA1* and *BRCA2* germline mutations among women with FTC.<sup>34,35</sup> Given the new understanding of preinvasive STIC lesions as a precursor to HGSC, the Society of Gynecologic Oncology now recommends that women with *BRCA1/2* mutations consider undergoing an RR-BSO between the ages of 35 and 40 years.<sup>36</sup> For those who decline an RR-BSO, the recommendation is to consider a salpingectomy followed by an oophorectomy once the woman is willing to accept menopause. The National Comprehensive Cancer Network recommends that carriers of *BRIP1*, *RAD51C*, and *RAD51D* mutations consider RR-BSO between 45 and 50 years of age, whereas average-risk women are encouraged to consider opportunistic salpingectomies when undergoing a hysterectomy or pelvic surgery or for sterilization (instead of traditional tubal ligation).<sup>37</sup>

### TREATMENT OF FTC

With the extreme similarities in clinical behavior between primary epithelial fallopian tube, ovarian, and peritoneal carcinomas, the treatment approach is the same, and no studies have focused exclusively on treatment of FTC. The

National Comprehensive Cancer Network recommends that any woman with suspected epithelial ovarian cancer be evaluated by a gynecologic oncologist, because optimal surgical debulking by a skilled physician is central to the initial management of patients with advanced, stage III or IV disease.<sup>38</sup> Studies have shown that the most significant prognostic factors for long-term survival are International Federation of Gynecology and Obstetrics stage at diagnosis and the volume of tumor remaining after debulking surgery.<sup>39</sup> Although the goal of cytoreductive surgery is no gross residual, debulking is considered optimal if residual disease is 1 cm or less in maximum diameter or thickness. For patients with early-stage disease at diagnosis, complete staging surgery is critical, because up to 30% of patients undergoing staging surgery will ultimately be upstaged.<sup>40</sup>

Given the importance of achieving optimal cytoreduction, the timing of radical debulking surgery continues to be controversial. ASCO states that although primary cytoreductive surgery is preferred for patients with a high likelihood of achieving optimal debulking, women with high

perioperative risk or a low likelihood of achieving optimal cytoreduction should receive neoadjuvant chemotherapy followed by possible interval surgery.<sup>41</sup> Several prospective studies have found higher complication rates and no survival advantage for upfront surgery when compared with neoadjuvant chemotherapy followed by interval cytoreduction.<sup>42,43</sup> However, these trials have been criticized for their low rates of optimal debulking and generally low progression-free survival (PFS) and overall survival. As the debate over timing of surgery is ongoing, the European Trial on Radical Upfront Surgery in Advanced Ovarian Cancer (TRUST) continues to randomly assign patients to neoadjuvant versus upfront surgery and it is hoped that this trial will help shed a more definitive light on this divisive topic.

For those patients who do undergo upfront cytoreductive surgery, adjuvant chemotherapy includes a platinum doublet, traditionally carboplatin and paclitaxel. The optimal route of and approach to administering the chemotherapy is ever evolving (Table 1). Conventional chemotherapy includes intravenous (IV) platinum and paclitaxel administered once every 3 weeks for six cycles.<sup>44,45</sup>

**TABLE 1.** Selection of First-Line Chemotherapy Trials in EOC

Trial	Control Arm	Experimental Arm	Outcome	HR (95% CI)	P
GOG 172	IV cisplatin + IV paclitaxel	IP cisplatin + IV or IP paclitaxel	PFS and OS significantly longer in experimental arm but also more toxicity (5 and 17 months, respectively)	PFS: 0.8* (0.64 to 1.00)	.05
				OS: 0.75* (0.58 to 0.97)	.03
JGOG 3016	IV carboplatin + IV paclitaxel once every 3 weeks	IV carboplatin once every 3 weeks + weekly IV paclitaxel	PFS and OS significantly longer in experimental arm (11 and 38 months, respectively)	PFS: 0.76 (0.62 to 0.91) OS: 0.79 (0.63 to 0.99)	.0037 .039
GOG 252	IV carboplatin + weekly IV paclitaxel + bevacizumab + maintenance bevacizumab	1. IP carboplatin + weekly IV paclitaxel + bevacizumab + maintenance bevacizumab	No significant difference in PFS (OS data not mature)	Control: reference	
		2. IP cisplatin + IV or IP paclitaxel + bevacizumab + maintenance bevacizumab		Arm 1: 0.947 (0.808 to 1.11)	.416
				Arm 2: 1.01 (0.858 to 1.18)	.727
GOG 218	IV carboplatin + IV paclitaxel + maintenance placebo	1. IV carboplatin + IV paclitaxel + bevacizumab + maintenance placebo	PFS longer in arm 3, bevacizumab throughout (4 months)	Control: reference	
		2. IV carboplatin + IV paclitaxel + bevacizumab + maintenance bevacizumab		Experimental arm 1: 0.908 (0.795 to 1.040)	.16
				Experimental arm 2: 0.717 (0.625 to 0.824)	< .001
GOG 262	IV carboplatin + IV paclitaxel once every 3 weeks + or – bevacizumab until progression	IV carboplatin + weekly IV paclitaxel + or – bevacizumab until progression	No significant difference in PFS; subgroup that did not received bevacizumab, longer PFS in experimental arm (4 months)	Did not receive bevacizumab: 0.62 (0.40 to 0.95)	.03
				Received bevacizumab: 0.99 (0.83 to 1.20)	.60

Abbreviations: EOC, epithelial ovarian carcinoma; GOG, Gynecologic Oncology Group; IV, intravenous; IP, intraperitoneal; JGOG, Japanese Gynecologic Oncology Group; OS, overall survival; PFS, progression-free survival.

\*Relative risk.

Because HGSC is primarily a peritoneal surface disease, intraperitoneal administration of the drugs was investigated, and it was found to improve both PFS and overall survival in patients who had minimal residual disease after debulking surgery.<sup>46,47</sup> Simultaneously, exploiting the hypothesis that extending the exposure time of a drug increase its antitumor activity, the Japanese Gynecologic Oncology Group noted significantly improved survival with a dose-dense weekly IV paclitaxel plus carboplatin regimen as compared with the conventional IV regimen.<sup>48</sup> Interestingly, when the dose-dense weekly IV regimen was compared with the conventional IV regimen in a European population (as part of the ICON8 trial), the study found no benefit to the weekly regimen.<sup>49</sup>

With the addition of novel agents such as the anti-vascular endothelial growth factor (VEGF) antibody, bevacizumab, to the chemotherapy regimens, the usefulness of the more toxic intraperitoneal and dose-dense IV regimens has come into question. In fact, Gynecologic Oncology Group (GOG) protocol 252 showed no survival advantage to intraperitoneal compared with a dose-dense IV regimen when both were administered with bevacizumab, and the results of GOG 262 suggest that bevacizumab also equalized the effects of dose-dense IV over the conventional once every 3 weeks IV regimen.<sup>50,51</sup>

### NOVEL THERAPIES IN FTC

Although the controversies over the timing of cytoreductive surgery and the mode of chemotherapy administration continue, promising novel targeted therapies for FTC have emerged. The humanized anti-VEGF monoclonal antibody, bevacizumab, has been readily adopted for treatment of recurrent HGSC. Elevated VEGF expression, such as that which occurs in HGSC, is associated with poor prognoses, and in several trials, bevacizumab, when used in combination with a platinum doublet, has shown improved PFS, although not overall survival. The OCEANS trial looked at the efficacy of adding bevacizumab to carboplatin plus gemcitabine in platinum-sensitive recurrent epithelial ovarian cancer and found a 4-month PFS advantage for women who received bevacizumab with the platinum doublet followed by bevacizumab maintenance compared with those receiving chemotherapy only and no maintenance treatment (hazard ratio [HR], 0.484 [95% CI, 0.388 to 0.605];  $P < .001$ ).<sup>52</sup> The AURELIA trial looked at patients with platinum-resistant disease and noted that in this patient population, adding bevacizumab to chemotherapy also provided a 3-month PFS advantage (HR, 0.48 [95% CI, 0.38 to 0.60];  $P < .001$ ).<sup>53</sup> Finally, GOG 213 noted that for patients with platinum-sensitive recurrent epithelial ovarian cancer, the addition of bevacizumab to standard chemotherapy of carboplatin and paclitaxel, followed by maintenance bevacizumab therapy until progression, improved the median overall survival by approximately 5 months (HR, 0.829 [95% CI, 0.683 to 1.005];

$P = 0.056$ ).<sup>54</sup> Most recently, on the basis of the results of GOG 218, bevacizumab has gained US Food and Drug Administration (FDA) approval for use in the adjuvant setting, in combination with carboplatin and paclitaxel, as part of initial therapy, and as monotherapy in the maintenance setting after completion of frontline treatment.<sup>55</sup> To date, bevacizumab has been FDA approved for the following uses in epithelial ovarian cancer: in combination with carboplatin plus paclitaxel, followed by bevacizumab single agent for stage III or IV disease after initial surgical resection; in combination with paclitaxel, pegylated liposomal doxorubicin, or topotecan for platinum-resistant recurrent epithelial ovarian cancer after no more than two prior chemotherapy regimens; and in combination with carboplatin plus paclitaxel or carboplatin plus gemcitabine, followed by bevacizumab single agent, for platinum-sensitive recurrent epithelial ovarian cancer.

PARP 1/2 are cellular enzymes that play a major role in DNA repair via recruitment of proteins involved in the base excision repair pathways. PARP inhibitors prevent the repair of single-strand breaks, leading to lethal double-strand breaks during DNA replication, and inhibit the non-homologous end-joining DNA repair pathway.<sup>56,57</sup> Both somatic and germline *BRCA1* and *BRCA2* mutations have been shown to predict response to PARP inhibitors in patients with epithelial ovarian cancer.<sup>58,59</sup>

There are currently three PARP inhibitors approved by the FDA for the management of epithelial ovarian cancer: olaparib, rucaparib, and niraparib (Table 2). Olaparib is approved as a treatment for patients with a germline *BRCA* mutation who have received at least three prior lines of chemotherapy.<sup>60</sup> Rucaparib is similarly approved as a treatment after at least two prior lines of chemotherapy but in patients with a germline or a somatic *BRCA* mutation.<sup>62</sup> All three drugs are approved for maintenance treatment of recurrence of epithelial ovarian cancer in patients with at least a partial response to platinum-based therapy.<sup>58,62,64</sup>

The most recent indication for olaparib is in the maintenance setting after completion of frontline chemotherapy. The SOLO-1 trial presented findings for *BRCA1/2* mutated patients who had at least a partial response to upfront platinum-based therapy: after a median follow-up of 41 months, the risk of death or disease progression was 70% lower for patients treated with maintenance olaparib as compared with placebo.<sup>61</sup> Given these practice-changing results, the drug recently received approval from the FDA for use as first-line maintenance therapy in *BRCA*-mutated epithelial ovarian cancer.

Trials currently underway will help further define the role of PARP inhibitors in the frontline maintenance setting: the PRIMA trial is looking at niraparib as maintenance in all patients, regardless of mutation status, who have had at

**TABLE 2.** PARP Inhibitors Used in EOC

PARP Inhibitor	FDA Approval Date	Indication	Data Supporting Use
Treatment			
Olaparib	12/2014	EOC in patients with deleterious germline <i>BRCA</i> mutation after three or more prior lines of therapy	Study 42 <sup>60</sup>
Rucaparib	12/2016	EOC in patients with deleterious germline or somatic <i>BRCA</i> mutation after two or more prior lines of therapy	ARIEL2 <sup>59</sup>
First-line maintenance			
Olaparib	12/2018	EOC in patients with deleterious germline <i>BRCA</i> mutation after at least partial response to first-line platinum-based chemotherapy	SOLO-1 <sup>61</sup>
Maintenance			
Niraparib	3/2017	Recurrent EOC after partial or complete response to platinum-based chemotherapy	NOVA <sup>58</sup>
Rucaparib	4/2017		ARIEL3 <sup>62</sup>
Olaparib	8/2018		SOLO-2 <sup>63</sup> ; Study 19 <sup>64</sup>

Abbreviations: EOC, epithelial ovarian carcinoma; FDA, Food and Drug Administration; PARP, poly(adenosine diphosphate [ADP]-ribose) polymerase.

least a partial response to upfront platinum-based therapy; the PAOLA-1 trial is combining bevacizumab with olaparib as maintenance therapy after at least a partial response to treatment with a combination of a platinum doublet and bevacizumab; and GOG 3005 is looking at veliparib in combination with carboplatin plus paclitaxel and as a maintenance therapy in patients with newly diagnosed advanced epithelial ovarian cancer.

### FUTURE DIRECTIONS

In recent years, hyperthermic intraperitoneal chemotherapy (HIPEC) has emerged as yet another player in the debate over the route of chemotherapy administration. HIPEC is a single intraoperative administration of warmed chemotherapy performed at the time of cytoreductive surgery. Complementing the benefit of intraperitoneal administration of the chemotherapy (a high concentration of the drug at its target location), hyperthermia leads to direct cell damage and increased sensitivity to chemotherapeutic agents.<sup>65</sup> In addition to multiple retrospective studies supporting the use of HIPEC, a recently published randomized trial showed increased PFS when HIPEC was used in patients with advanced-stage epithelial ovarian cancer during interval cytoreduction surgery.<sup>66</sup> However, another study, from Korea, examined HIPEC use at the time of primary or interval debulking surgery and did not see a similar survival benefit.<sup>67</sup> The safety profile was reassuring in both trials. Although HIPEC may be of benefit to some patients with epithelial ovarian cancer, additional work must be done to evaluate the optimal population and timing for this treatment modality.

Immunotherapy has had promising results in solid tumors such as melanoma and lung cancer. Recently, pembrolizumab (a programmed cell death protein [PD]-1

inhibitor), gained accelerated approval for the treatment of microsatellite instability high or mismatch repair protein deficient metastatic solid tumors. Unfortunately, only a small subset of epithelial ovarian cancer is microsatellite instability high or mismatch repair protein deficient and can benefit from this treatment. Trials are ongoing to better define the role of immunotherapy in epithelial ovarian cancer including, but not limited to, the addition of nivolumab to platinum-based neoadjuvant chemotherapy; avelumab (PD-L1 inhibitor) alone or in combination with the PARP inhibitor talazoparib as part of frontline platinum-based therapy (JAVELIN Ovarian 100 and JAVELIN Ovarian PARP 100 trials); a new anti-PD-1 antibody, TSR-042, combined with the PARP inhibitor, niraparib, and platinum-based therapy as first-line treatment (FIRST trial); atezolizumab (anti-PD-1 inhibitor) with bevacizumab and standard platinum-based therapy as first-line treatment (GOG-3015); combining nivolumab with the PARP inhibitor, rucaparib, as first-line maintenance after platinum-based therapy (ATHENA trial); and single-agent pembrolizumab or combination therapy of nivolumab and ipilimumab (cytotoxic T-cell lymphocyte-4 inhibitor) in recurrent epithelial ovarian cancer.

### CONCLUSION

Primary FTC is a rare and difficult-to-treat disease. Although historically FTC has been considered a subset of epithelial ovarian cancer, more recent research postulates that epithelial ovarian cancer actually originates in the fallopian tube from the precursor STIC lesion. Given that its clinical behavior is similar to that of epithelial ovarian cancer, FTC is managed in the same way: surgical debulking and platinum-based chemotherapy. Despite the many advances in the treatment and management of epithelial ovarian cancer made over the last several

decades, the survival rate has been slow to improve since the introduction of platinum-based chemotherapy. However, novel therapies for both primary and recurrent

disease, including the anti-VEGF antibody, PARP inhibitors, and immunotherapy, are changing the course of the disease and helping patients live longer, healthier lives.

## AFFILIATION

<sup>1</sup>Memorial Sloan Kettering Cancer Center, New York, NY

## CORRESPONDING AUTHOR

William P. Tew, MD, Memorial Sloan Kettering Cancer Center, 300 East 66 St, New York, NY 10065; e-mail: teww@mskcc.org.

## AUTHOR CONTRIBUTIONS

**Conception and design:** Marina Stasenko, William P. Tew

**Collection and assembly of data:** Marina Stasenko, Olga Fillipova

**Data analysis and interpretation:** Marina Stasenko

**Manuscript writing:** All authors

**Final approval of manuscript:** All authors

**Accountable for all aspects of the work:** All authors

## AUTHORS' DISCLOSURES OF POTENTIAL CONFLICTS OF INTEREST AND DATA AVAILABILITY STATEMENT

Disclosures provided by the authors and data availability statement (if applicable) are available with this article at DOI <https://doi.org/10.1200/JOP.18.00662>.

## REFERENCES

- Siegel RL, Miller KD, Jemal A: Cancer statistics, 2018. *CA Cancer J Clin* 68:7-30, 2018
- Tolia M, Tsoukalas N, Sofoudis C, et al: Primary extramammary invasive Paget's vulvar disease: What is the standard, what are the challenges and what is the future for radiotherapy? *BMC Cancer* 16:563, 2016
- National Cancer Institute: SEER Cancer Statistics Review (CSR), 1975-2015. [https://seer.cancer.gov/csr/1975\\_2015/](https://seer.cancer.gov/csr/1975_2015/)
- Kurman RJ, Shih IeM: Molecular pathogenesis and extraovarian origin of epithelial ovarian cancer--shifting the paradigm. *Hum Pathol* 42:918-931, 2011
- Senturk E, Cohen S, Dottino PR, et al: A critical re-appraisal of BRCA1 methylation studies in ovarian cancer. *Gynecol Oncol* 119:376-383, 2010
- Stewart SL, Wike JM, Foster SL, et al: The incidence of primary fallopian tube cancer in the United States. *Gynecol Oncol* 107:392-397, 2007
- Rosenblatt KA, Weiss NS, Schwartz SM: Incidence of malignant fallopian tube tumors. *Gynecol Oncol* 35:236-239, 1989
- Wethington SL, Herzog TJ, Seshan VE, et al: Improved survival for fallopian tube cancer: A comparison of clinical characteristics and outcome for primary fallopian tube and ovarian cancer. *Cancer* 113:3298-3306, 2008
- Lengyel E: Ovarian cancer development and metastasis. *Am J Pathol* 177:1053-1064, 2010
- Fathalla MF: Incessant ovulation--a factor in ovarian neoplasia? *Lancet* 2:163, 1971
- Colgan TJ, Murphy J, Cole DE, et al: Occult carcinoma in prophylactic oophorectomy specimens: Prevalence and association with BRCA germline mutation status. *Am J Surg Pathol* 25:1283-1289, 2001
- Piek JM, van Diest PJ, Zweemer RP, et al: Dysplastic changes in prophylactically removed fallopian tubes of women predisposed to developing ovarian cancer. *J Pathol* 195:451-456, 2001
- Labidi-Galy SI, Papp E, Hallberg D, et al: High grade serous ovarian carcinomas originate in the fallopian tube. *Nat Commun* 8:1093, 2017
- Yang HP, Murphy KR, Pfeiffer RM, et al: Lifetime number of ovulatory cycles and risks of ovarian and endometrial cancer among postmenopausal women. *Am J Epidemiol* 183:800-814, 2016
- Beral V, Doll R, Hermon C, et al: Ovarian cancer and oral contraceptives: Collaborative reanalysis of data from 45 epidemiological studies including 23,257 women with ovarian cancer and 87,303 controls. *Lancet* 371:303-314, 2008
- Iversen L, Fielding S, Lidegaard Ø, et al: Association between contemporary hormonal contraception and ovarian cancer in women of reproductive age in Denmark: Prospective, nationwide cohort study. *BMJ* 362:k3609, 2018
- Committee on Practice Bulletins--Gynecology, Committee on Genetics, Society of Gynecologic Oncology: Practice Bulletin No 182: Hereditary breast and ovarian cancer syndrome. *Obstet Gynecol* 130:e110-e126, 2017
- Kindelberger DW, Lee Y, Miron A, et al: Intraepithelial carcinoma of the fimbria and pelvic serous carcinoma: Evidence for a causal relationship. *Am J Surg Pathol* 31:161-169, 2007
- Tone AA: Taking the tube: From normal fallopian tube epithelium to ovarian high-grade serous carcinoma. *Clin Obstet Gynecol* 60:697-710, 2017
- McDaniel AS, Stall JN, Hovelson DH, et al: Next-generation sequencing of tubal intraepithelial carcinomas. *JAMA Oncol* 1:1128-1132, 2015
- Chen F, Gaitskell K, Garcia MJ, et al: Serous tubal intraepithelial carcinomas associated with high-grade serous ovarian carcinomas: A systematic review. *BJOG* 124:872-878, 2017
- Liao CI, Chow S, Chen LM, et al: Trends in the incidence of serous fallopian tube, ovarian, and peritoneal cancer in the US. *Gynecol Oncol* 149:318-323, 2018
- Trabert B, Coburn SB, Mariani A, et al: Reported incidence and survival of fallopian tube carcinomas: A population-based analysis from the North American Association of Central Cancer Registries. *J Natl Cancer Inst* 110:750-757, 2018
- McCluggage WG, Hirschowitz L, Gilks CB, et al: The fallopian tube origin and primary site assignment in extrauterine high-grade serous carcinoma: Findings of a survey of pathologists and clinicians. *Int J Gynecol Pathol* 36:230-239, 2017
- Medeiros F, Muto MG, Lee Y, et al: The tubal fimbria is a preferred site for early adenocarcinoma in women with familial ovarian cancer syndrome. *Am J Surg Pathol* 30:230-236, 2006
- Sherman ME, Piedmonte M, Mai PL, et al: Pathologic findings at risk-reducing salpingo-oophorectomy: Primary results from Gynecologic Oncology Group Trial GOG-0199. *J Clin Oncol* 32:3275-3283, 2014
- Shaw PA, Rouzbahman M, Pizer ES, et al: Candidate serous cancer precursors in fallopian tube epithelium of BRCA1/2 mutation carriers. *Mod Pathol* 22:1133-1138, 2009
- Committee on Gynecologic Practice: Committee opinion no. 620: Salpingectomy for ovarian cancer prevention. *Obstet Gynecol* 125:279-281, 2015

29. Rabban JT, Garg K, Crawford B, et al: Early detection of high-grade tubal serous carcinoma in women at low risk for hereditary breast and ovarian cancer syndrome by systematic examination of fallopian tubes incidentally removed during benign surgery. *Am J Surg Pathol* 38:729-742, 2014
30. Walsh T, Casadei S, Lee MK, et al: Mutations in 12 genes for inherited ovarian, fallopian tube, and peritoneal carcinoma identified by massively parallel sequencing. *Proc Natl Acad Sci USA* 108:18032-18037, 2011
31. Nielsen FC, van Overeem Hansen T, Sørensen CS: Hereditary breast and ovarian cancer: New genes in confined pathways. *Nat Rev Cancer* 16:599-612, 2016
32. Norquist BM, Harrell MI, Brady MF, et al: Inherited mutations in women with ovarian carcinoma. *JAMA Oncol* 2:482-490, 2016
33. Pennington KP, Walsh T, Harrell MI, et al: Germline and somatic mutations in homologous recombination genes predict platinum response and survival in ovarian, fallopian tube, and peritoneal carcinomas. *Clin Cancer Res* 20:764-775, 2014
34. Vicus D, Finch A, Cass I, et al: Prevalence of BRCA1 and BRCA2 germ line mutations among women with carcinoma of the fallopian tube. *Gynecol Oncol* 118:299-302, 2010
35. Cass I, Holschneider C, Datta N, et al: BRCA-mutation-associated fallopian tube carcinoma: A distinct clinical phenotype? *Obstet Gynecol* 106:1327-1334, 2005
36. Walker JL, Powell CB, Chen LM, et al: Society of Gynecologic Oncology recommendations for the prevention of ovarian cancer. *Cancer* 121:2108-2120, 2015
37. Daly MB, Pilarski R, Berry M, et al: NCCN guidelines insights: Genetic/familial high-risk assessment: Breast and ovarian, version 2.2017. *J Natl Compr Canc Netw* 15:9-20, 2017
38. National Comprehensive Cancer Network: Ovarian cancer including fallopian tube cancer and primary peritoneal cancer. NCCN Clinical Practice Guidelines in Oncology. 2018; Version 2.2018
39. Bristow RE, Tomacruz RS, Armstrong DK, et al: Survival effect of maximal cytoreductive surgery for advanced ovarian carcinoma during the platinum era: A meta-analysis. *J Clin Oncol* 20:1248-1259, 2002
40. Stier EA, Barakat RR, Curtin JP, et al: Laparotomy to complete staging of presumed early ovarian cancer. *Obstet Gynecol* 87:737-740, 1996
41. Wright AA, Bohlke K, Armstrong DK, et al: Neoadjuvant chemotherapy for newly diagnosed, advanced ovarian cancer: Society of Gynecologic Oncology and American Society of Clinical Oncology Clinical practice guideline. *J Clin Oncol* 34:3460-3473, 2016
42. Vergote IB, De Wever I, Decloedt J, et al: Neoadjuvant chemotherapy versus primary debulking surgery in advanced ovarian cancer. *Semin Oncol* 27:31-36, 2000
43. Kehoe S, Hook J, Nankivell M, et al: Primary chemotherapy versus primary surgery for newly diagnosed advanced ovarian cancer (CHORUS): An open-label, randomised, controlled, non-inferiority trial. *Lancet* 386:249-257, 2015
44. International Collaborative Ovarian Neoplasm Group: Paclitaxel plus carboplatin versus standard chemotherapy with either single-agent carboplatin or cyclophosphamide, doxorubicin, and cisplatin in women with ovarian cancer: The ICON3 randomised trial. *Lancet* 360:505-515, 2002
45. Ozols RF, Bundy BN, Greer BE, et al: Phase III trial of carboplatin and paclitaxel compared with cisplatin and paclitaxel in patients with optimally resected stage III ovarian cancer: A Gynecologic Oncology Group study. *J Clin Oncol* 21:3194-3200, 2003
46. Armstrong DK, Bundy B, Wenzel L, et al: Intraperitoneal cisplatin and paclitaxel in ovarian cancer. *N Engl J Med* 354:34-43, 2006
47. Trimble EL, Christian MC: Intraperitoneal chemotherapy for women with advanced epithelial ovarian carcinoma. *Gynecol Oncol* 100:3-4, 2006
48. Katsumata N, Yasuda M, Takahashi F, et al: Dose-dense paclitaxel once a week in combination with carboplatin every 3 weeks for advanced ovarian cancer: A phase 3, open-label, randomised controlled trial. *Lancet* 374:1331-1338, 2009
49. Clamp A, MI, Dean A, et al: CON 8: a GCG phase III randomised trial evaluating weekly dose-dense chemotherapy integration in first-line epithelial ovarian/fallopian tube/primary peritoneal carcinoma (EOC) treatment: results of primary progression-free survival (PFS) analysis. *Ann Oncol*, 2017. 28(Suppl. 5): abstract 9290\_PR
50. Walker JL, BM, DiSilvestro P, et al: A phase III clinical trial of bevacizumab with IV versus IP chemotherapy in ovarian, fallopian tube, and primary peritoneal carcinoma. NCI-supplied agent: bevacizumab (NSC #704865, IND # 7921). A GOG/NRG trial (GOG 252)
51. Chan JK, Brady MF, Penson RT, et al: Weekly vs. every-3-week paclitaxel and carboplatin for ovarian cancer. *N Engl J Med* 374:738-748, 2016
52. Aghajanian C, Blank SV, Goff BA, et al: OCEANS: A randomized, double-blind, placebo-controlled phase III trial of chemotherapy with or without bevacizumab in patients with platinum-sensitive recurrent epithelial ovarian, primary peritoneal, or fallopian tube cancer. *J Clin Oncol* 30:2039-2045, 2012
53. Pujade-Lauraine E, Hilpert F, Weber B, et al: Bevacizumab combined with chemotherapy for platinum-resistant recurrent ovarian cancer: The AURELIA open-label randomized phase III trial. *J Clin Oncol* 32:1302-1308, 2014
54. Coleman RL, Brady MF, Herzog TJ, et al: Bevacizumab and paclitaxel-carboplatin chemotherapy and secondary cytoreduction in recurrent, platinum-sensitive ovarian cancer (NRG Oncology/Gynecologic Oncology Group study GOG-0213): A multicentre, open-label, randomised, phase 3 trial. *Lancet Oncol* 18:779-791, 2017
55. Burger RA, Brady MF, Bookman MA, et al: Incorporation of bevacizumab in the primary treatment of ovarian cancer. *N Engl J Med* 365:2473-2483, 2011
56. Helleday T: The underlying mechanism for the PARP and BRCA synthetic lethality: Clearing up the misunderstandings. *Mol Oncol* 5:387-393, 2011
57. Patel AG, Sarkaria JN, Kaufmann SH: Nonhomologous end joining drives poly(ADP-ribose) polymerase (PARP) inhibitor lethality in homologous recombination-deficient cells. *Proc Natl Acad Sci USA* 108:3406-3411, 2011
58. Mirza MR, Monk BJ, Herrstedt J, et al: Niraparib maintenance therapy in platinum-sensitive, recurrent ovarian cancer. *N Engl J Med* 375:2154-2164, 2016
59. Swisher EM, Lin KK, Oza AM, et al: Rucaparib in relapsed, platinum-sensitive high-grade ovarian carcinoma (ARIEL2 Part 1): An international, multicentre, open-label, phase 2 trial. *Lancet Oncol* 18:75-87, 2017
60. Domchek SM, Aghajanian C, Shapira-Frommer R, et al: Efficacy and safety of olaparib monotherapy in germline BRCA1/2 mutation carriers with advanced ovarian cancer and three or more lines of prior therapy. *Gynecol Oncol* 140:199-203, 2016
61. Moore K, Colombo N, Scambia G, et al: Maintenance olaparib in patients with newly diagnosed advanced ovarian cancer. *N Engl J Med* 379:2495-2505, 2018
62. Coleman RL, Oza AM, Lorusso D, et al: Rucaparib maintenance treatment for recurrent ovarian carcinoma after response to platinum therapy (ARIEL3): A randomised, double-blind, placebo-controlled, phase 3 trial. *Lancet* 390:1949-1961, 2017
63. Hamanishi J, Mandai M, Ikeda T, et al: Safety and antitumor activity of anti-PD-1 antibody, nivolumab, in patients with platinum-resistant ovarian cancer. *J Clin Oncol* 33:4015-4022, 2015
64. Ledermann J, Harter P, Gourley C, et al: Olaparib maintenance therapy in platinum-sensitive relapsed ovarian cancer. *N Engl J Med* 366:1382-1392, 2012
65. Zivanovic O, Chi DS, Fillipova O, et al: It's time to warm up to hyperthermic intraperitoneal chemotherapy for patients with ovarian cancer. *Gynecol Oncol* 151:555-561, 2018
66. van Driel WJ, Koole SN, Sikorska K, et al: Hyperthermic intraperitoneal chemotherapy in ovarian cancer. *N Engl J Med* 378:230-240, 2018
67. Lim MC, Chang S-J, Yoo HJ, et al: Randomized trial of hyperthermic intraperitoneal chemotherapy (HIPEC) in women with primary advanced peritoneal, ovarian, and tubal cancer. *J Clin Oncol* 35: 5520-5520, 2017





**AUTHORS' DISCLOSURES OF POTENTIAL CONFLICTS OF INTEREST AND DATA AVAILABILITY STATEMENT**

**Fallopian Tube Carcinoma**

The following represents disclosure information provided by authors of this manuscript. All relationships are considered compensated. Relationships are self-held unless noted. I = Immediate Family Member, Inst = My Institution. Relationships may not relate to the subject matter of this manuscript. For more information about ASCO's conflict of interest policy, please refer to [www.asco.org/rwc](http://www.asco.org/rwc) or [ascopubs.org/jop/site/ffc/journal-policies.html](http://ascopubs.org/jop/site/ffc/journal-policies.html).

No potential conflicts of interest were reported.